

## HISTOLOGICAL CHANGES ON THE LUNG OF THE OFFSPRING FROM MOTHERS TREATED WITH URANYL ACETATE IN ALBINO RATS

\* Sabah N. Alwachy, \*\* Himen H. Othman, \* Nusaiba Amir

\* Department of Biology, College of Science, Baghdad University.

\*\* Department of Pathology, College of Veterinary, Sulaimania University.

### Abstract

This study was carried out to investigate the toxicity of the oral administration of uranyl acetate on the activity of some vital organs. Twenty mature females and ten males of albino rats were used in this experiment. They were divided into four equal groups. The first group (G1) used as control received only distilled water, while the others administrated orally by (50, 75 and 100 mg/kg/b.w. /day of uranyl acetate) for 70 days (10 weeks). Lung was taken from the offspring at two age stages (3<sup>rd</sup> and 5<sup>th</sup> weeks) for the current study.

Rats exposed to different doses of uranyl acetate showed a significant ( $p < 0.05$ ) decrease in body weight (b. w) of the offspring at 3<sup>rd</sup> week age, while b.w of the offspring revealed no significance at the 5<sup>th</sup> week age.

Furthermore, histopathological section of the lung of the offspring revealed the same lesions with differ severity according to the dose, including congestion in the pulmonary blood vessels specially branches of vein and in the alveolar capillaries, it was also showed, focal infiltration of mononuclear inflammatory cells (lymphocytes) and thickening of the alveolar wall in some area and infiltration of lymphocytes due to narrowing of the alveolar lumen (atelectasis) which lead to hyperplasia of the cellular elements.

### Introduction

Uranium (U), a natural and commonly radioactive element, is found in trace amounts in nature in the form of mineral (1). Although U exposure can result in both chemical and radiological toxicity, in general, chemical toxic effects from U compounds occur at lower exposure levels than radiological toxicity (2). Uranium, from the environment, enters human body by ingestion with food and drink, and by inhalation of airborne U-containing dust particles or aerosols (3, 4). The release of U in to the environment presents a threat to human and ecological health in many parts of the world (5). Soluble uranium and all nano-particles can cross the placenta, and these are particularly toxic to the rapidly developing embryo or fetus (6). Very high doses of U in drinking water can affect the development of the fetus in the laboratory animals (1). At low dose, U can damage the fetal brain, causing behavioral problems, such as hyperactivity and mental retardation. The underdeveloped immune and hormonal system of the fetus is more easily compromised than in a fully mature adult (7, 8). As well, U affects on postnatal development and behavior of the offspring (9).

### Materials and Methods

Thirty (10 males and 20 females) sexually mature laboratory breed males and females Sprague-Dawley Albino rats (*Rattus norvegicus*) of an average body weight of  $230 \pm 3.565$  gm and 12-15 weeks old. Animals were kept under the laboratory conditions (12h light:12h dark photoperiod), with controlled room temperature 25-28°C, good ventilation and were feed normal rodent pellets and tap water *ad Libitum*.

The rats were randomly divided into four groups. Female rats were mated with males (2:1) until copulation was detected. Finding of sperm in the vagina was indicated copulation and the day of detection were designated as Day 0 of gestation. Then the adult fertile females were treated with uranyl acetate dihydrate (UAD) by gavages 10 days before mating with untreated males, as well as during pregnancy and lactation for every day (9). The first group served as a control and only receive drinking water. However three concentration of uranyl acetate dissolved in water were administrated gavages to three other groups of females (50,75, 100 mg/ kg/ B.W/ day). The dose of (UAD) is based on results of previous studies (7,10,11).

The offspring were killed by cervical dislocation, then each group were scarified directly and lung was taken from the offspring at the two stage of age (3<sup>rd</sup> and 5<sup>th</sup> weeks).

## Results and Discussion

### 1. Body weight

In this study, significant weight loss was noticed in the b.w. of the offspring at 3<sup>rd</sup> week age compared with the control (Table (1); Fig.(1)). These results are consistent with (12) the main reason of this loss in b.w at this age is totally depending on mother's milk which contain U.A from exposed females (13), before that passes across the placenta during the pregnancy (14).

While, the b.w. of the offspring at 5<sup>th</sup> week age were not significantly different compare with the control, as in (Table (1); Fig.(1)), because they were feeding normal rodent pellets in addition of mothers milk. Therefore, the immune system was in progress at this stage (15, 16).

### 2. Effect of UA on development of offspring:

Uranium accumulates in the placenta and fetus (20). Developing embryos are exquisitely sensitive to chemical influences (21). The long-term consequence of fewer primordial follicles would lead to accelerated ovarian failure, resulting in an earlier menopause onset (22).

It is limited to one study in rats implanted with DU pellets, in which it was shown that uranium crossed the placental barrier and entered fetal tissue (23). For this reason, UA can reach the blood of fetus and distribute in the fetal tissues and cause lesions of some organs like liver, kidneys (24), and brain (25).

Had an increased number of dead young per litter, and that agreed with Paternain et al., (1989) (17). It is likely that the high doses of U in these studies led to reproductive toxicity (18, 19).

### 3. Histological changes of the lung:

The sections of lungs of these groups at two stage of age (3<sup>rd</sup> and 5<sup>th</sup> weeks) showed the same lesions, as a blood congestion and dilation to the alveolar capillaries in multilocal area, and slight hyperplasia changes indicated by the thickening of alveolar wall and formation of small papillary projections which protrude into the alveolar

lumen as shown in (Fig.3) .while, section of a normal histological structure of control lung showed a normal structure of the alveoli with a normal structure of inter alveolar septa as showed in (Fig.(2)).

At the same time, Section of Lung of offspring at 3<sup>rd</sup> week that treated with high doses showed peribronchial infiltration of mononuclear inflammatory cells mainly and diffuse of lymphocyte and hyperplasia to the alveolar macrophage as shown in (Fig.(5)). These lesions were depended on the dosages, this result agrees with (ATSDR 1999) (1). Maternal toxicity occurred in all uranium-treated groups as evidenced primarily by some deaths and decreases in body weight gain and body weight at termination (7).

The results in the present study reveal hemorrhage to the pulmonary blood vessels specially branches of vein and congestion to the alveolar capillaries in G4, G3 which is more sever than G2, as show in (Fig. (3), (6), (7)) these Capillary rupture at these site of congestion of lung because of the treatment with UA, may cause small foci of hemorrhage, breakdown and phagocytosis of the red cell debris can eventually result in small cluster of macrophage (26).

The sections of the offspring of this groups at two stage (3<sup>rd</sup> and 5<sup>th</sup> weeks age) were showed the same lesion with a simple variety between them, Section of Lung of offspring at 5<sup>th</sup> week (G2) Showed hyperplasia to the bronchial lymphoid tissue (lymphocyte) as shown in (Fig.(4)), also congestion to the branches of pulmonary blood vessels and hyperplasia to the alveolar interstitial cells as shown in (Fig.(5)). All of these lesions brewed from the toxicity of the UA (14).

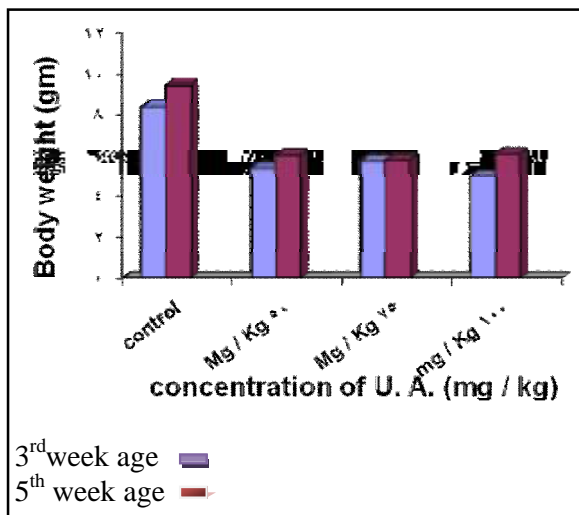
While the section of Lung of the offspring at 3<sup>rd</sup> week (G2) Showed congestion to the pulmonary blood vessels and Hyperplasia to the alveolar interstitial cells, lead to narrowing to the alveolar lumen (atelectasis), as (Fig.(5)). According to the U Medical Research Center, the toxic and radiological effects of U contamination may be weaken the immune system, and they may cause acute respiratory conditions like interstitial pneumonia that's cause from the oral administration of UA (27).

While, no adverse effects on the respiratory system were reported in rats given single oral doses of 118 mg uranium per kilogram body weight per day (U/kg/day) as uranyl acetate dihydrate (12).

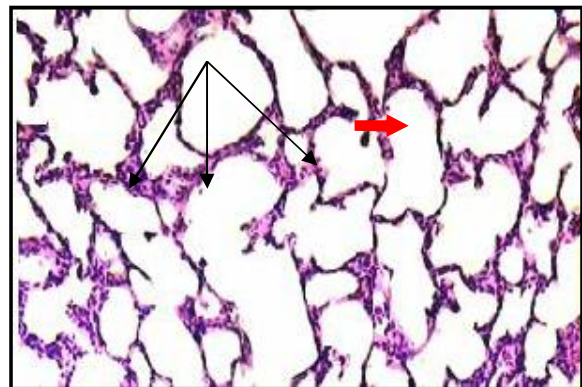
**Table (1)**  
*Body weight of the offspring at (3rd week) age and at (5th week) age.*

Treatment	B.w of the offspring at (3rd week)	B.w of the Offspring at ( 5th week ) age
	Mean ± SE	Mean ± SE
Control	8.400 ± 1.517 <sup>a</sup>	9.464 ± 1.166 <sup>a</sup>
50 mg/Kg	5.400 ± 2.074 <sup>b</sup>	6.022 ± 6.535 <sup>a</sup>
75 mg/Kg	5.750 ± 0.957 <sup>b</sup>	5.796 ± 1.181 <sup>a</sup>
100 mg/Kg	5.000 ± 2.000 <sup>b</sup>	6.098 ± 3.215 <sup>a</sup>

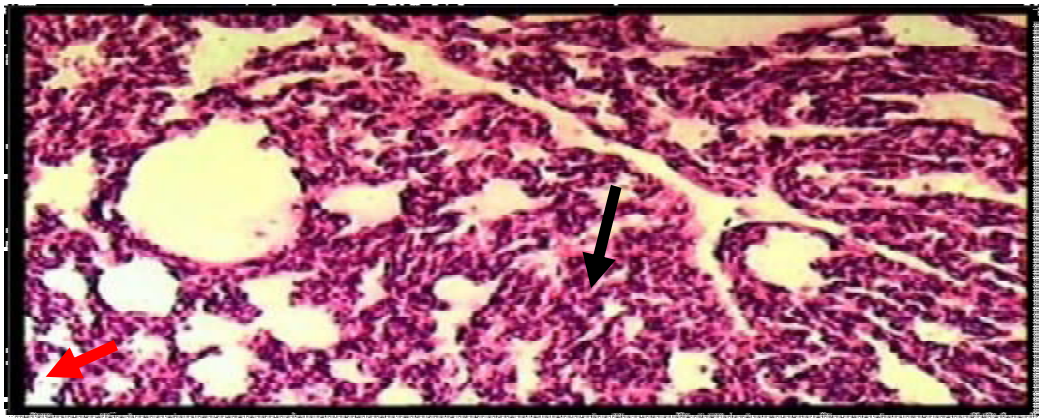
Different letters indicate significant differences ( $P < 0.05$ ).  
Similar letters indicate statistically no significant differences.  
B.W : body weight of offspring SE: Standard Error.



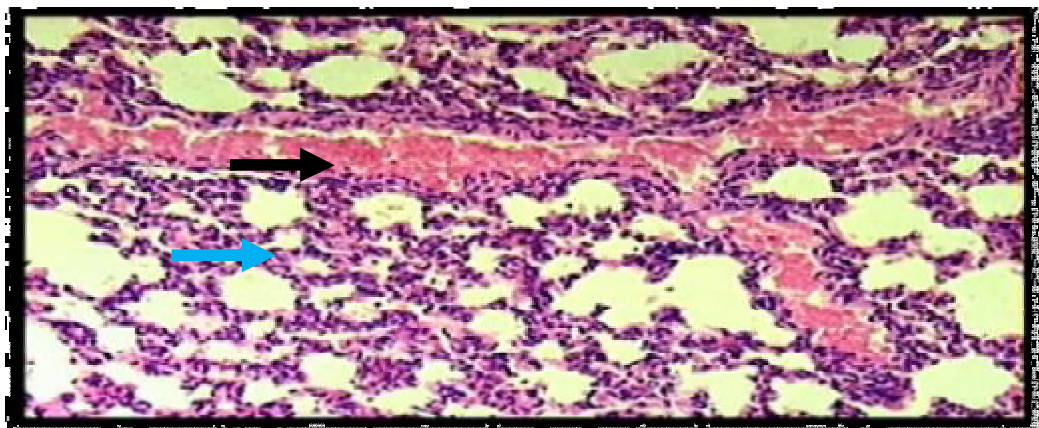
**Fig.(1):** Effect of different UA concentration on b.w. of offspring at 5<sup>th</sup> and 3<sup>rd</sup> week age.



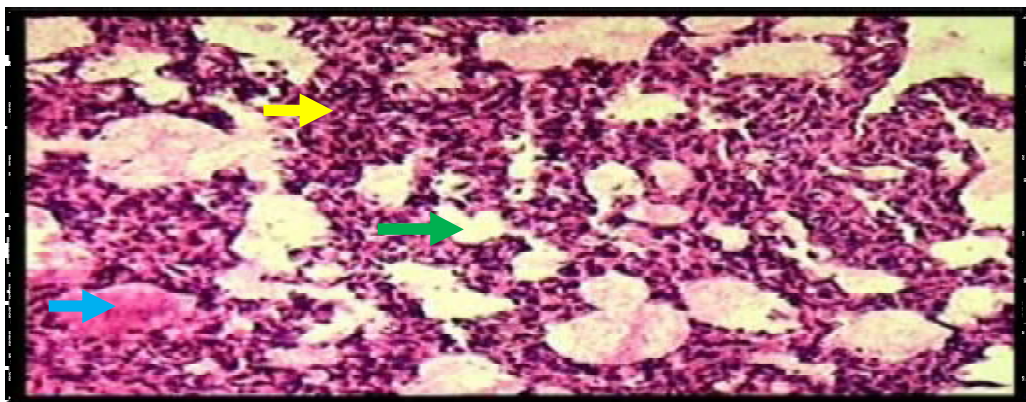
**Fig.(2):** Section of the lung of G1 showed, (→)thin wall of the alveoli, (—→)alveolar air space.



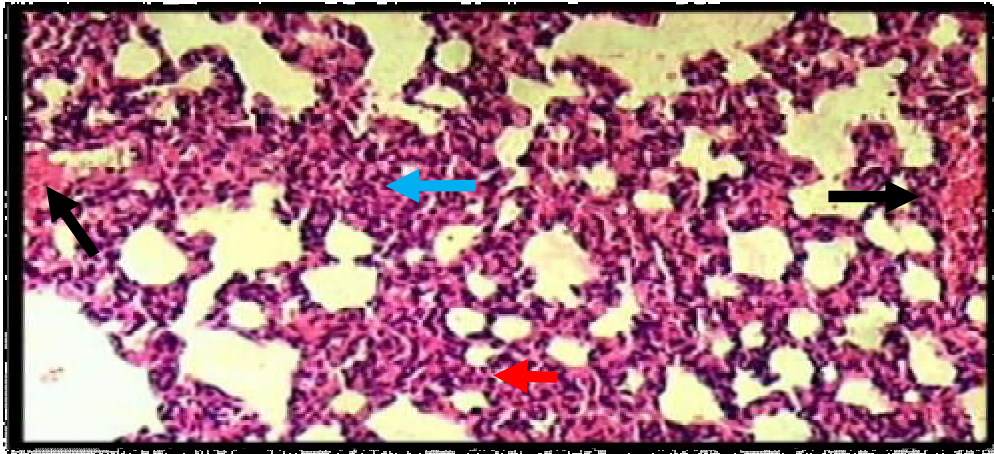
*Fig.(3): Section of Lung of offspring at 3rd week (G2) Shows ( —> ) narrowing to the alveolar lumen (atelectasis), and ( —> ) congestion to the alveolar capillaries, (100X).*



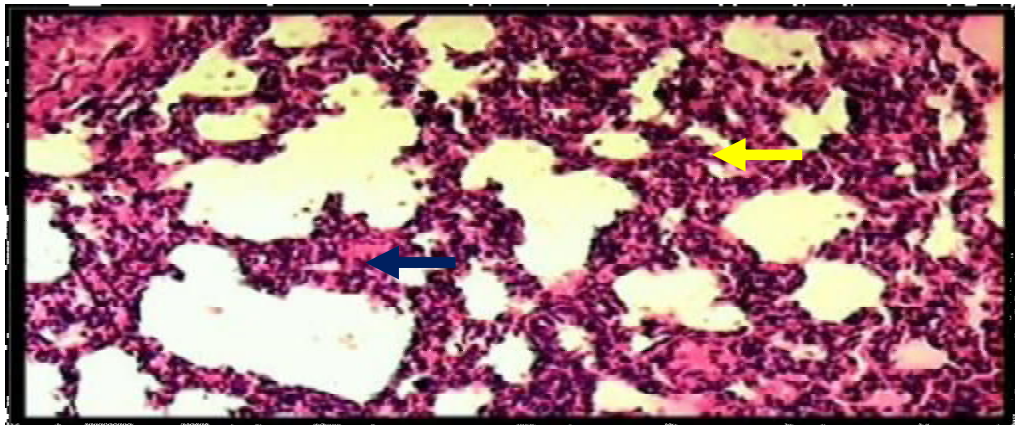
*Fig.(4):Section of Lung of offspring at 5th week (G2)Showed ( —> ) congestion to the branches of pulmonary blood vessels ( —> )Hyperplasia to the alveolar interstitial cells, (100X).*



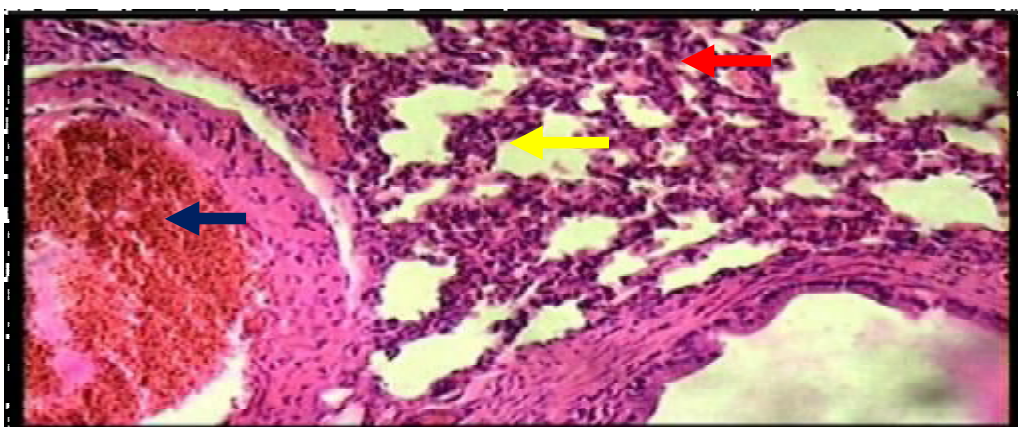
*Fig.(5):Section of Lung of offspring at 3rd week (G3) Showed ( —> )edematous protein fluid found with alveolar spaces, ( —> ) narrowing to the alveolar lumen, ( —> ) hyperplasia to the alveolar cellular elements lead to increased thickness of alveolar wall, (100X).*



*Fig.(6):Section of Lung of offspring at 5<sup>th</sup> week (G3) Showed( **→** ) Congestion and dilatation of alveolar capillaries ,( **←** ) increased thickness of alveolar wall, ( **←** ) narrowing of the alveoli, (100X).*



*Fig.(7): Section of Lung of offspring at 3rd week (G4) Showed,( **←** ) congestion and dilatation to the alveolar capillaries ,( **←** ) increasing thickness of alveolar wall,(X100).*



*Fig.(8): Section of Lung of offspring at 5<sup>th</sup> week (G4) Showed, ( **←** ) Congestion of the pulmonary blood vessels,( **←** ) narrowing of alveolar lumen(slit like)called atelectasis, ( **←** ) hyperplasia to the alveolar cellular elements,(100X) .*

## References

- [1] ATSDR (Agency for Toxic Substances and Disease Registry). Toxicological Profile for Uranium. U.S. Department of Health and Human Services, Public Health Service, Agency for Toxic Substances and Disease Registry, Atlanta, GA. (1999).
- [2] H.M. Hartmann, A. Monette and H.L. Avci, "Overview of toxicity data and risk assessment methods for evaluating the chemical effects of depleted uranium compounds", *Hum. Ecol. Risk Assess.*, Vol. 6, 2000, pp.851–874.
- [3] D.M. Taylor and S.K. Taylor, "Environmental uranium and human health", *Rev. Environ Health*, Vol.12, 1997, pp.147–157.
- [4] E. Craft, "Depleted and natural uranium: Chemistry toxicological effects", *J. Toxic. Environ. Health*, Vol. 7, No.4, 2004, pp. 297-317.
- [5] V.S.G. Murry, M.R. Bailel and G.B. Spratt, "Depleted uranium", *anew battle flied hazard. Lacet*, Vol.360, 2002, pp.31-32.
- [6] K.A. Benson and S.A. McBride, "Uranium levels in the fetus and placenta of female rats implanted with depleted uranium pellets prior to breeding", *Toxicologist*, Vol.36, 1997, pp.25.
- [7] M.L. Albina, Bellés, V. Linares, D.J. Sánchez, and J. L. Domingo, "Restraint stress does not enhance the uranium-induced developmental and behavioral effects in the offspring of uranium-exposed male rats" *.Toxicology*. Vol. 215, No.1, 2005, pp.69-79.
- [8] R. Bertell, "Depleted Uranium: All the questions about DU and gulf war syndrome are not yet answered". *Int. J. Health. Services*. Vol. 36, No.3, 2006, pp. 503-520.
- [9] D. J. Sánchez, J. L. Domingo, Albina, M. L.; Bellés, M.; Linares, V. "Exposure of pregnant rats to uranium and restraint stress: Effects on postnatal development and behavior of the offspring". *Toxicology*, Vol. 228, 2006, No. 2-3, pp. 323-332.
- [10] B.F.H. Al-Shemmary, "Histological and biochemical effects of uranyl acetate on male reproductive system in rats." Ph. D. Thesis. College of Veterinary Medicine, University of Baghdad. (2005).
- [11] J. H.Y. Al-Hilfy, "Effect of soybean seeds on liver function and apoptosis in liver, spleen and thymus in male rats treated with uranyl nitrate" *.Ph. D. Thesis*. College of science, University of Baghdad. (2007). (in Arabic)
- [12] J.L. Domingo, J.M. Llobet, J.M. Tomas, and J. Corbella, "Acute toxicity of uranium in rats and mice". *Bull. Environ. Contam. Toxicol.* Vol. 39, 1987, pp.168-174.
- [13] D. Stokols, I. J.M. Stelman, and C. Brabant, "Encyclopedia of occupational health and safety", *Int. Labor office (ILO)*, Vol.2, 1991, pp.1.
- [14] V. Morvai, E. Szakmáry, and G. Ungváry, "Hemodynamic Effects of Uranyl Acetate in Pregnant Rats", *Vol.10*, 2004, No.3, pp. 259–268.
- [15] A. Singha, S. Singha, "Postnatal modulation of hepatic biotranslactation system enzyme via translactation exposure of F1 mouse pups to turmeric and curcumin" *Cancer let*, Vol.96, 1995, No.1, pp.87-93.
- [16] A.L. Cheng, T.S. Shen, Y.G. Wang, "Phase I clinical trial with high risk or pre malignant lesion", *Anti-cancer Res*, Vol.21, 2001, pp. 28-29.
- [17] J.L. Paternain, J.L. Domingo, A. Ortega, J.M. Llobet, "The effects of uranium on reproduction, gestation and postnatal survival in mice". *Ecotoxicol. Environ Saf*, Vol. 17, 1989, pp. 291–296.
- [18] J.L. Domingo, "Reproductive and developmental toxicity of natural and depleted uranium", *Reprod Toxicol*, Vol. 15, 2001, pp. 603–609.
- [19] R. Hindin, D. Brugge, B. Panikkar, "Teratogenicity of depleted uranium aerosols: A review from an epidemiological perspective. *Environmental Health*", A Global Access Science Source, Vol. 4, 2005, No.17.